

The Pets Choice Newsletter

Issue No. 21

September 2005



August again saw the annual 'Paws-in-the-park' show held in Burrows Field, Leckhampton.

The show was again very well attended this year & provided a fun day out for both Children & Pets.

The *Pet's Choice* stand combined information displays with fun quiz sheets, raffles & of course free goody packs.

It was nice to see so many of our furry friends enjoying a fun day out at their show.

We hope that you all enjoyed the day & look forward to seeing you again next year.



.....our raffle first prize, *Eeyore* & a bottle-of-Bubbly.

The winners were presented at the Leckhampton Surgery several days after the show.

We would like to thank all those individuals & companies that contributed so generously in the provision of equipment, handouts & prizes for our stand.



MacDonald Veterinary Clinics

FAX telephone: 01242 577213
email address: admin@macdonaldvets.co.uk

6 Bethesda Street, Leckhampton, GL50 2AY
20 Cleevemount Road, Prestbury, GL52 3HG

01242 234392
01242 260144



internet domain: www.maconaldvets.co.uk

The Green Team




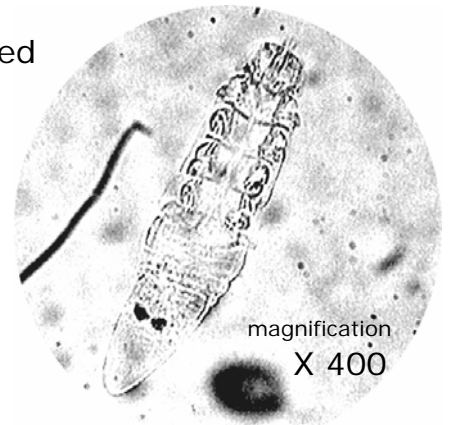
You don't have to like creepy crawlies for this job, but it certainly helps !!
Featured below are a number of microscopic parasites found on cats & dogs this summer, & identified using the video cam microscope at Bethesda Street.



Demodex canis is a worm-like mite that lives deeply embedded in the dog's skin. It is passed onto puppies from the bitch when they are suckling milk.

Puppies & young dogs suffering from this mange usually present at the surgery with swelling & infection of the skin of the front legs & face, those areas in close contact with the bitch prior to weaning.

Demodectic mange is diagnosed by examining skin scrapings using our video cam microscope. Treatment involves a series of shampoo treatments with concurrent antibiotic therapy.



Otodectes cynotis is the common ear mite that lives in the ear canal of the cat & dog.

Cats often tolerate this mite with little reaction, but dogs almost always react with sore & infected ears, *otitis externa*. The mite is just visible to the naked eye as a white spider-like creature & classically results in a dark brown discharge from the ear canal.

Treatment comprises polypharmacy ear drops, together with *Stronghold* spot on. This condition is contagious, so early diagnosis & treatment is important in multi-pet households.

Trombicula autumnalis, the *Harvest Mite* is truly like a miniature spider.

Dogs pick up this mite on their feet & this results in acute irritation & licking.

The mites can just be seen with the naked eye as bright orange coloured specs between the toes.

Diagnosis is confirmed by picking the parasites up using clear sticky tape & visualising under low-powered magnification on a microscope slide.

Treatment is relatively easy; these mites do not burrow & are quickly removed with *Frontline spray*.

Antibiotic & anti-inflammatory medication is sometimes also necessary to treat secondary skin lesions.

